

Healing Kinetics of Periapical Lesions Enhanced by the Apexum Procedure: A Clinical Trial

Zvi Metzger, DMD,^{*†} Ronen Huber, DMD,[‡] Dragos Slavescu, DMD,[§]
Dan Dragomirescu, DMD,^{||} Idan Tobis, BSc Eng,[‡] and Hadar Better, MD, DMD[‡]

Abstract

The new Apexum procedure (Apexum Ltd, Or-Yehuda, Israel) is based on a minimally invasive removal of periapical chronically inflamed tissues through a root canal access. Its goal is to enhance healing kinetics of periapical lesions. This clinical study was conducted to explore the safety and efficacy of this procedure. The Apexum procedure was applied, as a supplementary step, during conventional root canal treatment in 48 teeth with periapical lesions. Safety and efficacy were clinically and radiographically assessed and teeth of the Apexum-treated group were compared with 39 similar teeth treated by the same endodontic procedure with no additional intervention. No adverse events occurred in either the Apexum-treated or conventional treatment groups. Furthermore, healing kinetics was significantly enhanced in the Apexum-treated group ($p < 0.005$). At 3 and 6 months, 87% and 95% of the lesions in the Apexum-treated group, respectively, presented advanced or complete healing, whereas only 22% and 39% of the lesions in the conventional treatment group presented this degree of healing at 3 and 6 months, respectively. (*J Endod* 2009;35:153–159)

Key Words

Apexum, healing, minimally invasive, periapical lesions

From the Departments of *Endodontology and †Oral Biology, The Goldschleger School of Dental Medicine, Tel Aviv University, Tel Aviv, Israel; ‡Apexum Ltd, Or Yehuda, Israel; §Department of Stomatology, Tiu Maiorescu University, Bucarest, Romania and ||Private practice, Timisoara, Romania.

Supported by Apexum Ltd, Or-Yehuda, Israel.

Drs Metzger and Better serve as scientific consultants to and Dr Huber and Mr Tobis are employed by Apexum Ltd. Apexum Ltd is the manufacturer of the instruments tested in this study and provided financial support for this study.

Address requests for reprints to Dr Zvi Metzger, Department of Endodontology, School of Dental Medicine, Tel Aviv University, Ramat Aviv, Tel Aviv 94778, Israel. E-mail address: metzger@post.tau.ac.il.

0099-2399/\$0 - see front matter

© 2008 Published by Elsevier Inc. on behalf of the American Association of Endodontists.
doi:10.1016/j.joen.2008.11.019

Lesions of apical periodontitis represent an inflammatory response to bacterial infection of the root canal. Periapical radiolucency is the most pronounced clinical hallmark of these lesions. Most, but not all, periapical lesions will heal in response to properly performed endodontic treatment (1–3). However, an evidence-based estimation to assess the healing potential cannot be performed before 12 months after surgery (1, 2).

In an extensive study, Ørstavik concluded that (1) at 6 months, only 50% of the cases that will eventually heal show clear signs of healing (advanced and complete healing), and (2) at 12 months, 88% of the lesions that will eventually heal show clear signs of healing (1). This may imply that a case should ideally be followed for 12 months before the tooth may be considered a safe abutment (2).

Such a time schedule is difficult to follow in everyday clinical practice because both the dentist and patient are eager to finish the case with a permanent restoration as soon as possible. Consequently, this essential evidence-based information is not often clinically applied. Permanent restoration of the treated tooth as soon as possible is considered an unavoidable and thus acceptable practice. This approach will result in a certain percentage of endodontic failures in these recently restored endodontically treated teeth. Therefore, treatment protocols that may allow early determination of the healing potential of periapical lesions may be of a clinical advantage.

The prolonged healing process of many periapical lesions has been attributed to the activated macrophages in the lesion that may maintain their state of activation long after the initial cause of their activation has been eliminated by root canal treatment; namely, the activation state may outlive its useful purpose and become a burden by inhibiting resolution of the lesion (4, 5). The production of bone-resorbing cytokines by these cells may persist for many months after the completion of the root canal treatment, thus preventing resolution of the periapical bone defects (5).

The healing of similar lesions after apical surgery is much faster. Kvist and Reit (6) have shown that surgically treated lesions of apical periodontitis healed during the first 12 months with significantly enhanced kinetics compared with those treated with non-surgical retreatment. This was true even though both groups had similar healing rates over longer time periods. Fast healing of periapical lesions after apical surgery is a common clinical observation. These observations may indicate that surgical removal of the chronically inflamed periapical tissue may allow a fresh blood clot to form, which will then organize into an uncommitted granulation tissue and allows for faster healing (4, 5).

Performing apical surgery on every case with a periapical lesion will most likely enhance healing kinetics. Nevertheless, it can hardly be justified because surgery has repercussions for the well-being of the patient; swelling, pain, and discomfort are among the expected side effects (7). Furthermore, many anatomic locations preclude apical surgery either because of inaccessibility or risk to adjacent structures. In accordance, the American Association of Endodontists recommends performing apical surgery only in cases that cannot be treated otherwise (8).

Recently, a novel method was introduced that allows for the removal or debulking of periapical tissues without using scalpels, periosteal elevators, or sutures (5). This method is based on a device that removes the chronically inflamed periapical tissues through a root canal access by a procedure that is minimally invasive compared with open-flap apical surgery. The new technology (Apexum Ablator; Apexum Ltd, Or-Yehuda, Israel) has the possibility of providing some of the benefits of apical surgery

without the drawbacks of the conventional surgical procedure. This technological advancement may allow for the application of such a protocol in many apical periodontitis cases in which healing time is a critical factor.

Recently, preliminary animal trials of this procedure resulted in encouraging results in terms of both safety and efficacy of the procedure (9). The present study was conducted to clinically test the new Apexum procedure as a supplementary stage to conventional root canal treatment. It was aimed to assess the safety of the new procedure as well as to assess its efficacy in enhancing the healing kinetics of periapical lesions in humans.

Materials and Methods

Study Design

The study was designed as a prospective, multicenter, single-blinded, and randomized controlled superiority trial. It compared conventional endodontic treatment with a similar procedure supplemented by the Apexum procedure.

Patients

The patient population consisted of 87 healthy individuals referred for endodontic treatment in three dental clinics located in Bucharest and Timisoara, Romania. Patient age was ≥ 18 years. Patients suffering from uncontrolled hypertension, uncontrolled diabetes mellitus, chronic renal failure, hematologic diseases, HIV, or osteoporosis treated with bisphosphonates were excluded. Exclusion criteria also included steroid therapy in excess of 5 mg/d of prednisone, prior head and neck irradiation therapy, and conditions that require bacterial endocarditis prophylaxis.

The study protocol was reviewed and approved by the Ethics Committee of the Ministry of Health of Romania and by the local Ethics Committee of the participating clinics or the universities with which they are affiliated. Each patient agreed to participate in the study and in its follow-up and signed a detailed informed consent form.

Inclusion and Exclusion Criteria and Allocation of Teeth

Teeth selected for the study were single-rooted teeth with a single root canal and a mature, fully formed apex. All teeth had a necrotic and infected pulp with apical periodontitis, resulting in a radiolucent periapical lesion of a 3- to 6-mm diameter. All lesions had a 4 or 5 score when evaluated using the periapical index (10).

Teeth with previous root canal fillings, abnormal root canal anatomy, or any other reason that may prevent a common root canal treatment were excluded. Teeth located in anatomic areas in which enucleation of the periapical tissues may jeopardize nearby structures, such as the mandibular nerve, the maxillary sinus, and so on were also excluded. Nonrestorable teeth, teeth with advanced periodontal disease, and those with clinical evidence of a missing buccal bony plate over the periapical defect were also excluded from this study.

Teeth were randomly allocated to Apexum-treated or conventional treatment groups. Randomization was done by opening sealed envelopes with an assignment to either Apexum-treated or conventional treatment groups and resulted in an approximately 1:1 ratio between the groups. When more than one tooth was in the same patient, randomization was done by assigning the right or more mesial tooth to the conventional treatment group, whereas the left or more distal tooth was allocated to the Apexum-treated group.

The Apexum Devices

The Apexum kit consists of two devices, the Apexum NiTi Ablator and Apexum PGA Ablator, designed to be used sequentially (Fig. 1). Both instruments are for single use and were provided by Apexum Ltd.

The Apexum NiTi Ablator consists of a specially preshaped Nitinol wire. One end is bent and is designed to enter the periapical tissues through the root canal and apical foramen, whereas the other end has a latch-type connector to allow its operation by a low-speed contra-angle handpiece. The bent part is initially concealed in a straight super elastic Nitinol tube that serves as a sheath allowing its introduction up to the apical foramen (Fig. 1A). When pushed, the wire emerges from its sheath and through the apical foramen and resumes its preshaped form (Fig. 1B, C). The special retrograde design of the bent part allows it to rotate in the periapical soft tissues at 200 to 250 rpm and coarsely grind them while being deflected from the surrounding bone (Fig. 1C). The Nitinol sheath is used first to allow the introduction of the prebent Nitinol wire to the apical foramen and second to allow unobstructed rotation of the wire in the root canal without twisting of the wire.

The second device is the Apexum PGA Ablator, built from a Nitinol shaft, equipped on one end with a latch-type connector to allow its operation by a low-speed contra-angle handpiece (Fig. 1D). At the other end, a bioabsorbable filament is attached, which is designed to enter the periapical bony crypt and rotate at 5,000 to 7,000 rpm, turning the tissue that was initially minced with the NiTi Ablator into a thin suspension that may be flushed through the root canal.

Conventional Treatment Group: Endodontic Procedure

Teeth in the conventional treatment group were subjected to a common two-visit root canal treatment. In the first visit, the tooth was isolated, all carious lesions or previous restorations removed, and the crown restored using glass-ionomer cement. An access cavity was then prepared, root canal located, and the root canal cleaned and shaped using hand and nickel-titanium rotary files (ProFile; Maillefer, Ballaigues, Switzerland) with intermittent rinsing with 5.5% sodium hypochlorite. Working length was established at 1 mm short of the biological apex of the root as determined by using an apex locator (Root ZX, Morita, Japan). Root canal preparation was carried out up to a #40 K-file, as a master apical file, with a #20 K-file repeatedly used to ensure apical patency. Root canals were then dried with sterile paper points and dressed with calcium hydroxide. A sterile cotton pellet was placed in the pulp chamber, and the access cavity was sealed with a glass-ionomer cement temporary filling until the next visit. On the second visit, which took place 7 to 24 days after the first visit, the tooth was checked for any symptoms such as pain, sensitivity to percussion, or swelling. If such symptoms were present, the first procedure was repeated and a third visit scheduled. When the tooth was asymptomatic, the dressing was washed out with sodium hypochlorite assisted with hand files. The root canal was checked for the absence of suppuration or exudate, dried with sterile paper points, and obturated using lateral condensation with AH-26 Plus (Dentsply De Trey, Konstanz, Germany) and gutta-percha. The access cavity was sealed with a glass-ionomer cement temporary filling followed by taking a post-operative radiograph. Many of the teeth were permanently restored by the referring dentists while in other cases the glass-ionomer temporary restoration was kept through the observation period and its integrity checked when the follow-up radiographs were taken.

Apexum-Treated Group: Conventional Endodontic Treatment Supplemented With the Apexum Procedure

The treatment protocol in the Apexum-treated group was identical to that of the conventional treatment group with the addition of the Apexum procedure. More specifically, the first visit procedure was iden-

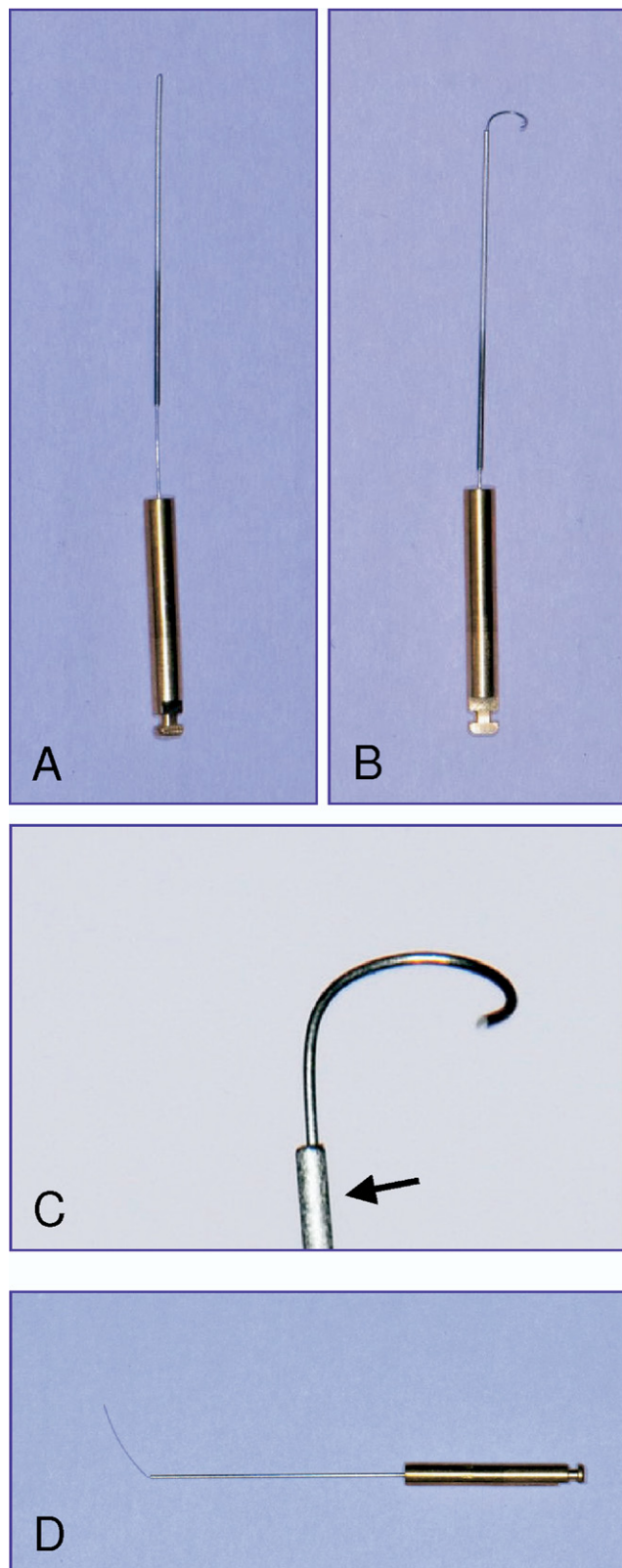


Figure 1. The Apexum devices. (A) The Apexum Ni-Ti Ablator in its sheath. (B) The Apexum NiTi Ablator pushed in and extruded from its sheath (arrow). (C) An enlarged view of the active part of the Apexum NiTi Ablator. (D) The Apexum PGA Ablator.

tical in both groups. In the second visit, an identical procedure was also performed until the stage at which the root canal was ready for obturation.

At this stage, the Apexum procedure was performed. A #20 K-file was passed through the apical foramen and beyond the apex to verify patency. It was followed by a rotary #30 file (Profile .04, Maillefer) that was passed 1 mm beyond the apical foramen, creating a passage with a $\sim 330\text{-}\mu\text{m}$ diameter.

The Apexum NiTi Ablator was then inserted, while encased in its sheath, to the working length as established at the cleaning and shaping stage (first visit). The sheath was stabilized to the occlusal surface of the tooth using glass-ionomer cement. The Nitinol filament was then pushed manually through the enlarged apical foramen and into the periapical tissues. The filament was first rotated manually to verify mobility with no solid obstruction and then attached to a low-speed contra-angle handpiece. The NiTi Ablator was then rotated in the periapical tissues for 30 seconds at 200 to 250 rpm to initially mince the tissue (Fig. 2). The stabilizing glass-ionomer cement was then removed and the NiTi Ablator withdrawn from the root canal with its sheath to examine it for any mechanical damage or missing parts. The root canal was rinsed with sterile saline, and the Apexum PGA Ablator was manually inserted through the root canal and into the periapical tissues. It was then connected to a low-speed contra-angle handpiece and rotated for 30 seconds at 5,000 to 7,000 rpm to turn the minced tissues into a thin suspension. Next, it was withdrawn from the root and examined for any mechanical damage or missing parts.

The tissue suspension was now washed out with sterile saline solution by using a syringe adapted with a 30-G blunt needle. The needle was passed through the enlarged apical foramen into the periapical space, and the solution was slowly and gently injected to flush the tissue suspension out. The cross-sectional area between the enlarged apical foramen and the outer surface of the needle is 3.4 times larger than that of the needle's lumen. This facilitated an unobstructed backflow and prevented pressure buildup in the periapical crypt. Nevertheless, special attention was given to visually monitor the backflow of the blood red suspension through the root canal continuously so that pressure buildup did not occur in the periapical space. To allow for continuous monitoring, aspiration was performed at a distance from the access cavity so that the operator could visually evaluate the in- and outflow rates. The suspension turned pale during the process, and the flushing was stopped and the needle removed when clear solution appeared. The root canal was then dried with sterile paper points and obturation

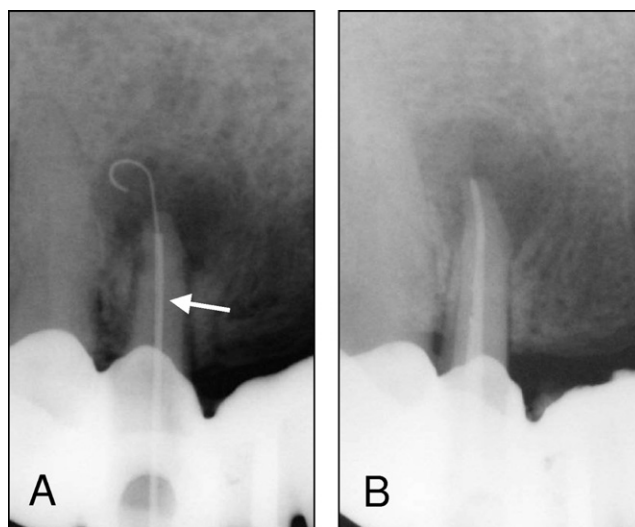


Figure 2. The Apexum NiTi Ablator in a periapical lesion. (A) The NiTi Apexum Ablator fully extruded from its sheath (arrow) and into the periapical lesion. (B) Root canal filling performed immediately after the Apexum procedure.

conducted as in the conventional treatment group followed by a glass-ionomer cement temporary filling and a postoperative radiograph. Restorations were performed as in the conventional treatment group.

The Apexum procedure was performed under local anesthesia, provided in a manner similar to that used for tooth extraction or surgical intervention. With some experience, it took an additional 7 to 10 minutes compared with a conventional root canal treatment.

Radiographic Procedures

All radiographs were taken using a digital sensor (Schick Technologies, Long Island City, NY). Two periapical radiographs of each tooth were taken, before, and immediately after the endodontic procedure, with follow-up radiographs taken 3 and 6 months thereafter.

Clinical Follow-up

Each patient in both the Apexum-treated and conventional treatment groups was instructed to record pain, swelling, or any other adverse event that occurred after treatment and if he/she required any analgesics or other medication after the endodontic procedure. Patients were contacted by telephone a week after completion of the root canal treatment and asked (1) if there was any discomfort or pain, (2) whether analgesics were needed, (3) if there was swelling, and (4) if there were any other postoperative events. At the 3- and 6-month follow-up visits, the patient was questioned again, and the tooth and surrounding tissues were clinically examined and the findings recorded.

The Evaluation of Results: Adverse Events

Adverse events were recorded and used to evaluate the safety of the Apexum procedure as compared with conventional root canal treatment. These included swelling, required antibiotics, or having an unscheduled appointment or any other events that occurred immediately after the procedure or during the follow-up period.

Analgesics used after surgery with no unscheduled dental appointment were not considered as procedure-related adverse events because some pain or discomfort are common after a routine root canal treatment of cases with apical periodontitis, and these cases were monitored and recorded separately. They also were used for comparison of the Apexum protocol to conventional root canal treatment.

The Evaluation of Results: Radiographic Records

Radiographic follow-up was used to evaluate the efficacy of the Apexum procedure compared with conventional root canal treatment. The radiographic image of the periapical lesion was evaluated from a set of radiographs.

Follow-up radiographs, taken at 3 and 6 months, were viewed together and compared with those taken immediately after treatment. The change in the radiographic image of the periapical lesion was evaluated and defined. The following four categories (9) were used: (1) "no healing," no reduction in the size of the lesion or enlargement of the lesion; (2) "minor healing," a clear, but minor, decrease in the size of the lesion; (3) "advanced healing," a substantial decrease in the size of the lesion but not a complete healing; and (4) "complete healing," the lesion disappeared completely. Some residual widening of the periapical periodontal ligament was also considered as complete healing.

Two reviewers were used, an oral-maxillofacial surgeon and an endodontist. Each reviewer evaluated and scored each set of radiographs independently. When both reviewers agreed, then the score was registered. When disagreement occurred, then another reviewer (endodontist) was brought in and the issue was discussed to obtain an agreed-on score. All reviewers were initially calibrated by evaluating sets of similar radiographs and were blinded as to the group to which a given tooth belonged.

TABLE 1. AEs and Postoperative Pain

	Apexum Procedure	Conventional Root Canal Treatment
Intraoperative AEs	0/48	0/39
Postoperative AEs	0/46	0/39
Postoperative pain	4/46 (8.7%)	12/39 (30.8%)

The scores were later dichotomized (2, 9) so that "no healing" and "minor healing" were considered together as "nonhealing," whereas the "significant healing" and "complete healing" were considered together as "healing."

Sealer Extrusion

Sealer extrusion that occurred during root canal obturation was blindly examined and evaluated from radiographs. Three categories were used: (1) no sealer extrusion, (2) a small sealer puff (similar to those encountered when patency was preserved throughout the endodontic procedure), and (3) large sealer puffs (bigger than those that are common in the technique described earlier).

Statistical Analysis

The primary safety endpoint was treatment-related adverse events (AEs). The secondary safety endpoint was the occurrence of pain that required analgesic. The primary efficacy endpoint was healing at 6 months, defined dichotomously for each periapical lesion as "healing" or "nonhealing." The secondary efficacy endpoint was similarly to the dichotomized healing scores at 3 months. Healing was also evaluated on the full four-category healing scale, as described previously, at the 3- and 6-month follow-up visits. A chi-square and Fisher exact test were applied to test the significance of healing differences between the Apexum-treated and conventional treatment groups at the 3- and 6-month follow-ups. All tests were two-tailed, and p values of 5% or less were considered statistically significant. Data analysis was performed by using SAS software, version 9.1 (SAS Institute, Cary, NC).

Results

Safety: AEs, Pain, and Mechanical Failures

Intraoperative AEs

The endodontic treatment per se was uneventful in all cases for both groups. Periapical tissue removal using the Apexum protocol was uneventful in all 48 cases in the Apexum-treated group (Table 1).

Postoperative AEs

Subjects were called within 7 days of the procedure; 46 of the 48 subjects in the Apexum-treated group and all 39 in the conventional treatment group were available at this time point. No treatment-related adverse events were recorded in either the Apexum-treated or the conventional treatment groups (Table 1). More specifically, there was no swelling and no need for an unscheduled dental appointment in any of the patients.

Postoperative Pain

Some postoperative discomfort or pain within 2 to 3 days of treatment was recorded in 31% of the cases treated by conventional endodontic treatment. When the Apexum procedure was applied, as a supplementary step to conventional endodontic treatment, the occurrence of postoperative discomfort or pain was reduced to 9% of the cases; thus, the Apexum procedure was significantly less painful postoperatively than conventional root canal treatment ($p < 0.05$, Table 1). Neither swelling nor severe pain were recorded for any of the cases treated.

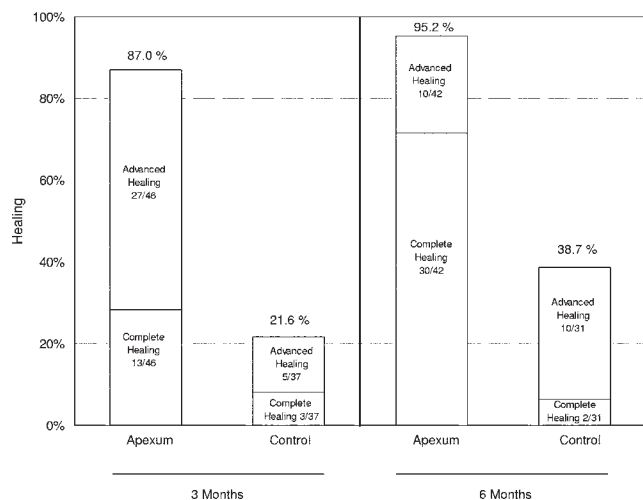


Figure 3. Healing in the Apexum and conventional treatment (control) groups; dichotomized data.

Mechanical Failures

No mechanical failure occurred when applying either the Apexum NiTi Ablator or the PGA Ablator in the Apexum-treated group. Each device was only used one time in a total of 48 procedures during the present study.

Efficacy

Of the 48 periapical lesions treated with the Apexum protocol, 46 were available for radiographic evaluation at 3 months and 42 at 6 months. Of the 39 periapical lesions treated by conventional endodontic treatment, 37 were available for radiographic evaluation at 3 months and 31 at 6 months.

Healing Rates at 3 Months

“Healing” (complete healing or advanced healing) at 3 months was evident in 40 of 46 patients in the Apexum-treated group (87.0%) compared with 8 of 37 (21.6%) in the conventional treatment group (Fig. 3). Healing in the Apexum-treated group at 3 months occurred with a significantly higher frequency than in the conventional treatment group ($p < 0.005$).

Complete healing at 3 months (Table 2) was evident in 13 of 46 patients (28.3%) in the Apexum-treated group compared with 3 of 37 (8.1%) in the conventional treatment group. The occurrence of complete healing in the Apexum group was significantly higher than in the conventional treatment group ($p < 0.005$).

Healing at 6 Months

“Healing” at 6 months was evident in 40 of 42 patients in the Apexum-treated group (95.2%) compared with 12 of 31 patients (38.7%) in the conventional treatment group (Fig. 3). Healing in the

Apexum-treated group occurred with a significantly higher frequency at 6 months than in the conventional treatment group ($p < 0.005$).

Complete healing at 6 months was evident in 30 of 42 patients (71.4%) in the Apexum-treated group compared with 2 of 31 patients (6.5%) in the conventional treatment group (Table 2). Complete healing in the Apexum-treated group occurred with a significantly higher frequency than in the conventional treatment group ($p < 0.005$). A representative case from the Apexum group is presented in Figure 4. The dichotomized healing results at 3 and 6 months are presented in Figure 3.

Sealer Extrusion and Its Effect

Sealer extrusion occurred in both groups. In the Apexum-treated group, no puff was found in 54% of the cases, small puff in 34%, and larger puffs in 12% of the cases. In the conventional treatment group, no puffs appeared in 60% of the cases, small puff in 30%, and larger puffs in 10% of the cases. The difference between the groups was not significant. Neither the small sealer puffs nor the bigger ones interfered with healing of the lesions (Figure 5).

Discussion

The new Apexum procedure represents a shift from the current endodontic paradigm. Foremost, it does not limit the endodontic intervention only to removing the cause (bacteria) and then allowing the host to heal at its own pace, and, furthermore, the device enters the periapical lesion far beyond the apical foramen, a process expected by many operators to result in a flare-up or severe symptoms (11, 12). Therefore, a preliminary animal study was required before a clinical trial was attempted. The application of the Apexum procedure for treatment of induced periapical lesions in dogs resulted in no AEs, and the healing results supported the hypothesis that the removal of periapical chronically inflamed tissues will enhance healing kinetics of the lesions (9).

In the present clinical trial, the Apexum procedure resulted in no events of severe postoperative pain or postoperative swelling and in only a few events of postoperative discomfort or mild pain (9%). None of the patients who were subjected to this protocol reported any other adverse events. This is of particular interest because conventional root canal treatment resulted in some discomfort or pain for 31% of the cases. It is also important to note that when a conventional, open-flap, apical surgery is performed, many of the patients do experience pain, swelling, or both and usually need analgesics in the days after surgery. Furthermore, Kvist and Reit (7) found that 23% of the patients going through apical surgery reported a loss of working days because of such postoperative symptoms. The Apexum minimally invasive procedure seems to be gentle on the patient’s well-being, with far less symptoms than conventional, open-flap apical surgery and even conventional root canal treatment.

These results are rather surprising because the current paradigm is that the insertion of an endodontic instrument far beyond the apical foramen should be avoided by all means because it is likely to cause a “flare-up,” a painful exacerbation of the periapical inflammatory process (11, 12).

TABLE 2. Periapical Healing as Evaluated From a Radiographic Follow-up

Healing	Apexum Procedure		Conventional Root Canal Treatment	
	3 Months	6 Months	3 Months	6 Months
Complete	13/46	30/42	3/37	2/31
Advanced	27/46	10/42	5/37	10/31
Minor	3/46	0/42	8/37	8/31
None	3/46	2/42	21/37	11/31
	87.0%	95.2%	21.6%	38.7%
	13.0%	4.8%	78.4%	61.3%

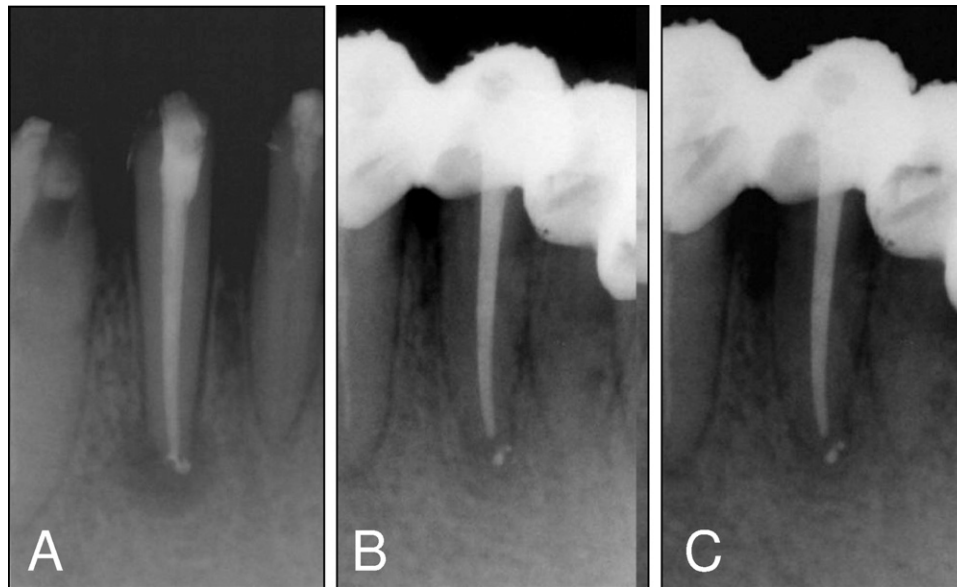

Figure 4. Healing of a periapical lesion after the Apexum procedure. (A) Immediate postoperative radiograph. (B) A follow-up radiograph at 3 months. (C) A follow-up radiograph at 6 months.

It should be noted that the Apexum procedure is substantially different from simple overinstrumentation during root canal treatment. The last traumatizes the tissue and may also introduce bacterial antigens into a tissue containing immunoglobulins directed against these antigens and that is primed to respond to them (5, 13, 14). When this happens, acute inflammatory response with resulting edema is likely to occur in the periapical tissue, resulting in a flare-up (5, 11, 12). Such a flare-up did not appear in a single case of the 48 subjected to the Apexum procedure. It is most likely that with the removal or major debulking of the periapical chronically inflamed tissues, the mechanisms that could otherwise lead to such a flare-up were also removed. This may explain the quite uneventful postoperative clinical behavior.

Healing kinetics (the progress of healing with time), as judged from follow-up radiographs, were enhanced in the group treated with the Apexum procedure. At 3 months, 87% of the periapical lesions were either completely healed or in advanced stages of healing, whereas in the conventional treatment group only 22% showed such a trait. At 6 months, 95% of the lesions in the Apexum-treated group showed advanced or complete healing, whereas conventional root canal treatment

resulted with such progress in only 39% of the cases. Therefore, it may be concluded that the Apexum protocol allows for a faster healing process than that provided by conventional root canal treatment.

Healing at 6 months in the conventional treatment group was almost identical to that calculated from Ørstavik's study (1). In his extensive study, 50% of the cases that eventually healed showed clear signs of healing at 6 months. Taking into consideration the long-term healing rate of 75%, this results in 37.5% of the treated lesions that presented clear signs of healing at 6 months compared with 39% in the conventional treatment group in the present study.

Whether the Apexum procedure was able to remove all of the periapical inflammatory tissue, as is usually attempted in conventional apical surgery, is beyond the scope of the present study. Most likely, the Apexum procedure removed all of this inflamed tissue in some lesions, whereas major debulking occurred in others. In any case, the procedure created conditions that allowed for faster healing of the lesions. Because the term "removal" may be misinterpreted as "complete removal," the term "removal or debulking" was chosen to describe the mechanical effect of the Apexum procedure on the periapical tissues.

Another potentially controversial issue is the widening of the apical foramen to form a passage of a 330- μm diameter. The extent of root canal preparation at its apical part has been the subject of much debate (15–20). Many of the current nickel-titanium rotary file systems limit the instrumentation at this area to diameters of 250 to 300 μm while avoiding any preparation in the constriction of the apical foramen itself. This is largely done because of technical considerations, to allow obturation with heat-softened gutta-percha methods that may otherwise result in the extrusion of material beyond the apex. Biological considerations point otherwise (17–20). The apical constriction and the apical foramen itself may harbor bacterial biofilms that may be left untouched by the limited apical preparations (15). Furthermore, the natural dimensions of the apical part of the canal are frequently much wider than 250 to 300 μm (16). This recently led to suggesting larger apical preparations and the use of hybrid techniques to achieve them (17–20). The natural dimensions of the apical foramen itself may often reach sizes of 350 or even 600 μm (21, 22). The foramen may become even wider when apical resorption takes place, as is often encountered in

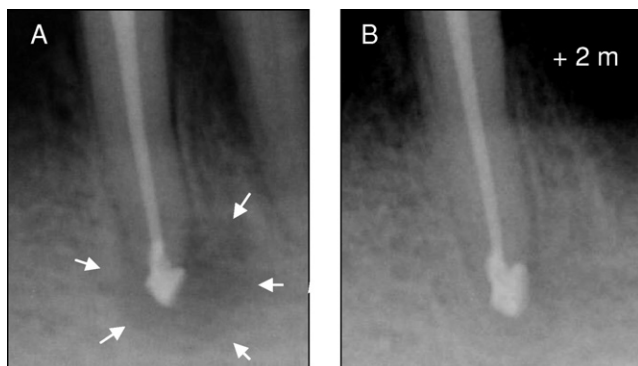


Figure 5. Healing of a periapical lesion after the Apexum procedure. (A) The immediately postoperative radiograph; note accidental major extrusion of the obturation material, a single case of its type in the whole study. Arrows indicate the extent of the periapical lesion. (B) A follow-up radiograph at 2 months.

roots with apical periodontitis, such as those treated in the present study (23, 24). The similar patterns of sealer extrusion that were observed in the present study may express this well-established phenomenon.

Considering all the previously mentioned items, enlarging the apical foramen to a diameter of 330 μm , as required by the Apexum procedure, probably does not result in a major change to its size in many or even most cases of apical periodontitis.

Passing through the apical foramen with a #30 rotary file followed by the repeated passage of the Apexum devices and the irrigation needle may have yet another potential outcome. Bacterial biofilms that potentially reside in this area may potentially remain undisturbed by the current minimal apical intervention concept of many of the rotary nickel-titanium file systems. The Apexum procedure is more likely to eliminate them or at least mechanically disturb them to the extent of disrupting the host-bacteria equilibrium in favor of the host. Such processes may have also contributed to the enhanced healing observed in the present study. Nevertheless, additional studies focusing on this specific issue will be required before the contribution of this process to the total enhanced healing may be estimated.

At the present stage, with a follow-up period of 6 months, it is too early to predict if the final healing rate at 48 months (25) (as opposed to healing kinetics) will also be affected, which is likely the case. It has been well documented that 15% to 25% of periapical lesions fail to heal in response to adequate endodontic treatment. Some of these failures have been attributed to factors that are most likely to be affected by the Apexum procedure, such as extraradicular infections or cystic formations within the periapical lesion. Nevertheless, evaluation of the healing rate (as opposed to healing kinetics) will call for longer follow-up periods and much larger groups of patients. Such studies will soon be in progress. These may verify whether the healing rate of periapical lesions can also be affected by the new Apexum procedure.

Conclusions

The Apexum procedure resulted in no adverse events. The Apexum procedure resulted in significantly less postoperative discomfort or pain than conventional root canal treatment or than that reported for conventional apical surgery. The Apexum procedure resulted in a significantly faster periapical healing as compared with conventional root canal treatment ($p < 0.005$). The removal or debulking of the periapical inflamed tissues, using the Apexum procedure, seems to enhance healing kinetics with no adverse events.

References

1. Ørstavik D. Time course and risk analysis of the development and healing of chronic apical periodontitis in man. *Int Endod J* 1996;29:150–5.

2. Friedman S. Prognosis of initial endodontic treatment. *Endod Topics* 2002;2:59–88.
3. Figdor D. Apical periodontitis: a very prevalent problem. *Oral Surg Oral Med Oral Pathol Oral Radiol Endod* 2002;94:651–2.
4. Metzger Z. Macrophages in periapical lesions. *Endod Dental Traumatol* 2000;16:1–8.
5. Metzger Z, Abramovitz I. Periapical lesions of endodontic origin. In: Ingle JI, Bakland LK, Baumgartner JC, eds. *Ingle's Endodontics*. 6th ed. Hamilton, Canada: BC Decker; 2008: 494–519.
6. Kvist T, Reit C. Results of endodontic retreatment: a randomized clinical study comparing surgical and nonsurgical procedures. *J Endod* 1999;25:814–7.
7. Kvist T, Reit C. Postoperative discomfort associated with surgical and nonsurgical endodontic retreatment. *Dental Traumatol* 2000;16:71–4.
8. Appropriateness of Care and Quality Assurance Guidelines. 3rd ed. Chicago, IL: American Association of Endodontists; 1998.
9. Metzger Z, Huber R, Tobis I, Better H. Enhancement of healing kinetics of periapical lesions in dogs by the Apexum procedure. *J Endod* (in press).
10. Ørstavik D, Kerekes K, Eriksen HM. The periapical index: a scoring system for radiographic assessment of apical periodontitis. *Endod Dental Traumatol* 1986;2: 20–34.
11. Siqueira J. Reaction of periradicular tissues to root canal treatment: benefits and drawbacks. *Endod Topics* 2005;10:123–47.
12. Baumgartner JC, Rosenberg PA, Hoen MM, Lin LM. Treatment of endodontic infections, cysts, and flare-ups. In: Ingle, JI Bakland, LK Baumgartner, eds. *JC Ingle's Endodontics*. 6th ed. Hamilton, Canada: BC Decker; 2008:690–712.
13. Baumgartner JC, Falkler WAJ. Reactivity of IgG from explant cultures of periapical lesions with implicated microorganisms. *J Endod* 1991;17:207–12.
14. Kettering JD, Torabinejad M, Jones SL. Specificity of antibodies present in human periapical lesions. *J Endod* 1991;17:213–6.
15. Nair PNR. Light and electron microscopic studies of root canal flora and periapical lesions. *J Endod* 1987;13:29–39.
16. Kerekes K, Tronstad L. Morphological observations of root canals of human molars. *J Endod* 1977;3:114–8.
17. Spangberg LS. The wonderful world of rotary root canal preparation. *Oral Surg Oral Med Oral Pathol Oral Radiol Endod* 2001;92:479.
18. Card SJ, Sigurdsson A, Ørstavik D, Trope M. The effectiveness of increased apical enlargement in reducing intracanal bacteria. *J Endod* 2002;28:779–83.
19. Walsch H. The hybrid concept of nickel-titanium rotary instruments. *Dent Clin North Am* 2004;48:183–202.
20. Peters OA. Current challenges and concepts in the preparation of root canal systems: a review. *J Endod* 2004;30:559–67.
21. Morfis A, Sylaras SN, Georgopoulou M, Kernani M, Prountzos F. Study of the apices of human permanent teeth with the use of scanning electron microscope. *Oral Surg Oral Med Oral Pathol* 1994;77:172–6.
22. Briseño-Marroquin B, El-Syed MAA, Willershausen-Zonnchen B. Morphology of the physiological foramen: I. Maxillary and mandibular molars. *J Endod* 2004;30: 321–8.
23. Furusawa M, Asai Y. SEM observations of resected root canal ends following apicoectomy. *Bull Tokyo Dent Coll* 2002;43:7–12.
24. Vier FV, Figueiredo JAP. Internal apical resorption and its correlation with the type of apical lesion. *Int Endod J* 2004;37:730–7.
25. Strindberg LD. The dependence of the results of pulp therapy on certain factors. An analytic study based on radiographic and clinical follow up examination. *Acta Odontol Scand* 1956;14(suppl):21.